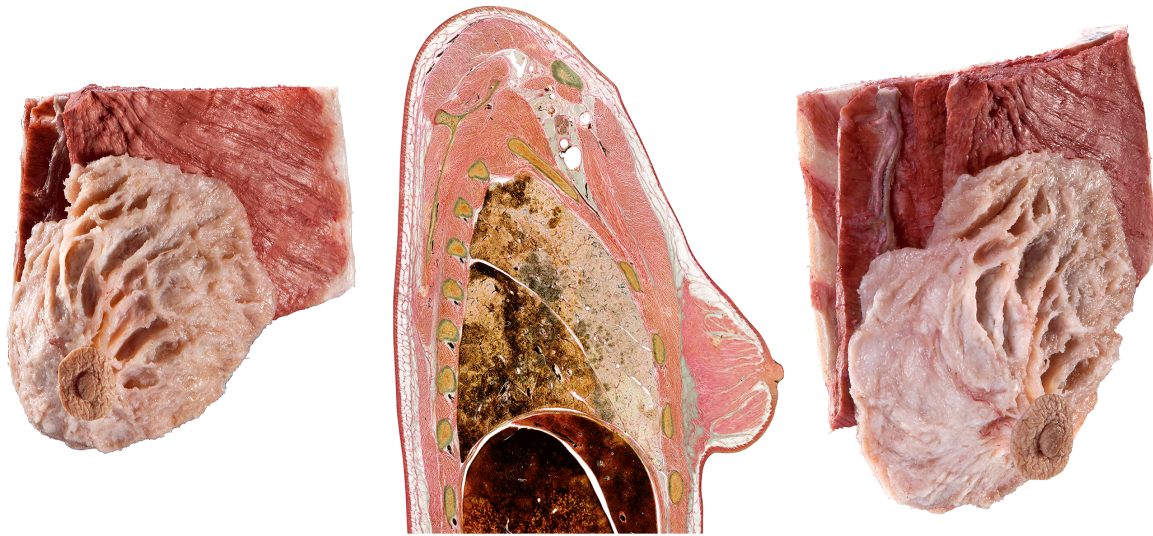




Silicone Plastinates - Torso Specimens - **Mammary Gland**



Mammary Gland

HP0406

- gland lobules, lactiferous ducts and sinuses have been exposed
- with the adjoining part of the thoracic wall
- dissection of the supplying arteries
- includes an anatomy glass (as in the picture)

