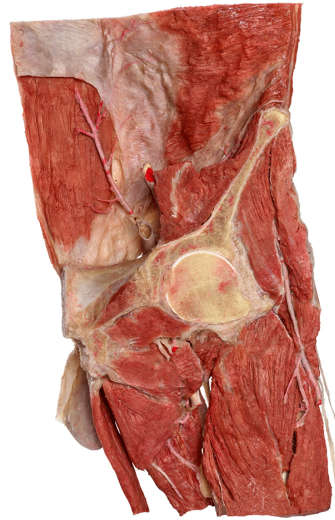
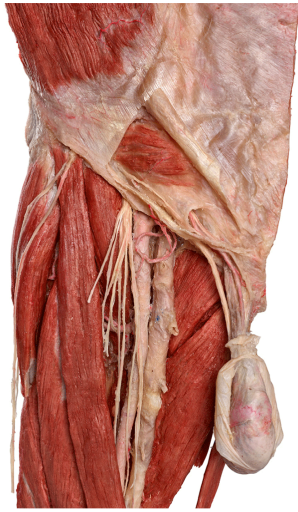



Silicone Plastinates - Torso Specimens - **Inguinal Region**



Inguinal Region and Femoral Triangle

HP0410

- frontal cut of the male pelvis and upper part of the thigh through the hip joint (one side)
- lower part of the abdomen represents inguinal region with the inguinal canal
- content of the inguinal canal is displayed
- testis, epididymis and spermatic cord are dissected
- structures within the femoral triangle are exposed
- stand included

